JOURNAL OF THE AMERICAN COLLEGE OF CARDIOLOGY
© 2018 PUBLISHED BY ELSEVIER ON BEHALF OF THE
AMERICAN COLLEGE OF CARDIOLOGY FOUNDATION

VOL. 72, NO. 23, 2018

JACC REVIEW TOPIC OF THE WEEK

Arrhythmic Mitral Valve Prolapse

JACC Review Topic of the Week

Marc A. Miller, MD,[a] Srinivas R. Dukkipati, MD,[a] Mohit Turagam, MD,[a] Steve L. Liao, MD,[b] David H. Adams, MD,[c] Vivek Y. Reddy, MD[a]

ABSTRACT

There is an increasing awareness of the association between mitral valve prolapse and sudden cardiac death. There are several clinical risk factors associated with an increased risk of mitral valve prolapse-related sudden cardiac death, most of which can be evaluated with noninvasive diagnostic modalities. For example, characteristic changes on the electrocardiogram (T-wave inversions in the inferior leads), complex ventricular ectopy, a spiked configuration of the lateral annular velocities by echocardiography, and evidence of myocardial fibrosis by cardiac magnetic resonance imaging have all been implicated as markers of risk. Herein, the authors review the reported incidence of sudden death to mitral valve prolapse, the clinical profile of at-risk patients, and the basic components necessary to initiate and perpetuate ventricular arrhythmias (substrate and trigger) as well as potential interventions to consider for those at highest risk. (J Am Coll Cardiol 2018;72:2904-14) © 2018 Published by Elsevier on behalf of the American College of Cardiology Foundation.

Mitral valve prolapse (MVP), estimated to affect 1% to 3% of the general population, is classically defined as a superior displacement of the mitral leaflet(s) of >2 mm during systole and myxomatous degeneration of the mitral leaflets, resulting in a maximal leaflet thickness of at least 5 mm during diastasis (1). MVP carries a heterogenous prognosis with clinical outcomes dependent on multiple variables, including patient age, degree of mitral regurgitation (MR), left ventricular (LV) ejection fraction, ventricular ectopy, and atrial diameter (2). The adverse sequelae of primary MVP include significant MR, heart failure, infective endocarditis, stroke, cardiac arrhythmias, and, perhaps the least appreciated but most devastating complication, sudden cardiac death (SCD) (3). Although the association between MVP and SCD was first reported decades ago, the risk was initially believed to be exceedingly small, and there was scant literature to suggest otherwise (4). More contemporary observational studies suggest that MVP-related SCD, owing to sustained ventricular arrhythmias (VAs), may occur more frequently, with an estimated annual risk of 0.2% to 1.9% (3,5-8). Consequently, there is an increasing interest in MVP-related SCD as well as effective techniques to identify those patients at higher risk for a fatal arrhythmic event. Recent studies have yielded new insights into the pathophysiology and risk factors for the development of VAs in patients with MVP. This review focuses on arrhythmic causes of SCD in patients with degenerative MVP (Barlow's disease).

Listen to this manuscript's audio summary by *JACC* Editor-in-Chief Dr. Valentin Fuster.

From the [a]Helmsley Electrophysiology Center, Icahn School of Medicine at Mount Sinai, New York, New York; [b]Division of Noninvasive Cardiovascular Imaging, Icahn School of Medicine at Mount Sinai, New York, New York; and the [c]Department of Cardiovascular Surgery, Icahn School of Medicine at Mount Sinai, New York, New York. Dr. Miller has served as a consultant to Boston Scientific. Dr. Dukkipati has received research grant support from Biosense Webster. Dr. Reddy has received research grants from and served as a consultant for Biosense Webster, Boston Scientific, and Abbott. Dr. Adams has received grant support from Medtronic; has served as the National Co-Principal Investigator of the Medtronic APOLLO FDA Pivotal Trial, NeoChord ReChord FDA Pivotal Trial, Medtronic CoreValve U.S. Pivotal Trial, and Abbott TRILUMINATE Pivotal Trial; and has received royalty agreements through Mount Sinai School of Medicine with Medtronic and Edwards Lifesciences. All other authors have reported that they have no relationships relevant to the contents of this paper to disclose.

Manuscript received June 12, 2018; revised manuscript received August 23, 2018, accepted September 4, 2018.

ISSN 0735-1097/$36.00 https://doi.org/10.1016/j.jacc.2018.09.048

INCIDENCE OF SCD ATTRIBUTED TO MVP

The reported incidence of SCD due to mitral valve prolapse varies depending on the methods used to evaluate the cause of death (e.g., autopsy vs. survivors), the study population (e.g., age, athletes), available clinical information (e.g., electrocardiogram [ECG], echocardiogram), and forensic analysis performed (e.g., genetics) (9).

Autopsy-based studies have reported wide incidence rates for MVP-related SCD. This variability exists in part because of the uncertain cause-effect relationship between the finding of MVP at autopsy and the arrhythmic SCD (10). Therefore, the confirmed presence of MVP on examination is rarely classified as "unequivocally related" to the SCD event, even when exhaustive examinations cannot identify another potential etiology. Rather, MVP it is more often classified as "undetermined" or "probably related" to the fatal event. For example, an autopsy study could not determine the presumptive cause of death in 50% of the young women (35 to 44 years of age) studied, and so those with those cases (n = 13) were classified as "sudden cardiac death of unexplained etiology." However, of those "unexplained" cases, more than one-half were noted to have mitral valve prolapse at autopsy (11). This lack of classification may result in an underestimation of the true incidence of MVP-related SCD, especially when autopsy studies show that MVP remains one of the most common causes of death in otherwise healthy young patients where MVP is offered as a classification (4,12,13).

A 21-year prospective clinical-pathological investigation in Italy (<35 years of age) found MVP to be the third most common cardiac condition associated with SCD with an incidence of 12%, with arrhythmogenic right ventricular dysplasia (24%) and atherosclerotic coronary artery disease (20%) being the only diagnoses that were more common (14). In registries of competitive and noncompetitive athletes, the incidence of SCD attributable to MVP ranged from 2% to 4%, similar to community-based studies of nonathletes (2.3%) (5,13). The true annual risk of SCD for the individual patient with MVP, however, remains unknown. While observational studies have estimated the risk at 0.9% to 1.9% per year, there is significant heterogeneity in methodology and study populations. Additionally, in studies that do report the incidence of MVP-related sudden death, it remains unclear what valve morphology criteria were present (e.g., redundant and thickened), which could impact the true estimation of its association. Select studies that report the incidence of MVP-related SCD are shown in **Table 1**. Finally, while the denominator is large (i.e., the number of patients with MVP), the precise numerator (i.e., the number of patients who have aborted or fatal VAs) is unknown, due to the absence of large longitudinal registries. Therefore, it is prudent to focus on patients with additional risk factors for the development of sustained VAs (8).

RISK FACTORS

Several clinical risk factors appear to be associated with an increased risk of SCD in patients with MVP (**Central Illustration**). For the purposes of this review, we have separated them by baseline characteristics and diagnostic modality: electrocardiography, echocardiographic, and magnetic resonance imaging (5,6,15).

BASELINE CHARACTERISTICS

MVP related life-threatening VAs appear to occur more often in young females, with some studies demonstrating that 70% to 90% of affected individuals are women (16). The reason for this gender discrepancy is unknown and may be multifactorial. MVP is more common in women and they are more likely to have bileaflet prolapse and more valve thickening, and less likely to undergo valve surgery (17).

ELECTROCARDIOGRAPHY

A majority of patients (>75%) with MVP-related SCD demonstrate characteristic T-wave abnormalities on the surface ECG with biphasic or inverted T-waves in the inferior leads (II, III, aVF) (6,15) (**Figure 1**). In our opinion, the presence of this finding in MVP patients should prompt the clinician to further investigate an individuals' risk profile, acknowledging, however, that this finding alone is not enough to consider a patient at high risk, as inverted T waves can be found in up to 40% of MVP patients without a history of sustained VAs (18).

Premature ventricular contractions (PVC) are a common finding in the general population of MVP patients with and without SCD. Although patients without accompanying MR exhibit fewer complex PVCs, they are still a relatively common finding (~40% to 50%) compared with the general population (19). Complex PVCs usually refer to those that

ABBREVIATIONS AND ACRONYMS

CMR = cardiac magnetic resonance

ECG = electrocardiogram

LGE = late gadolinium enhancement

LV = left ventricular

MAD = mitral annular disjunction

MR = mitral regurgitation

MRI = magnetic resonance imaging

MVP = mitral valve prolapse

PVC = premature ventricular contraction

SCD = sudden cardiac death

VA = ventricular arrhythmia

VF = ventricular fibrillation

VT = ventricular tachycardia

TABLE 1 Select Studies of MVP and Sudden Death

First Author, Year (Ref. #)	Study	Patients With MVP	Age (yrs)*	Women (%)	LVEF (%)*	≥Moderate MR (%)	Biphasic or TWI in Inferior Leads (%)	VAs on ECG/ Holter (%)	Comments
Bui et al., 2017 (29)	Retrospective	41	50	3.0	63 ± 7	N/A	N/A	43.7	Myocardial fibrosis by CMR
Perazzolo et al., 2016 (30)	Prospective	52	44	63.0	65	None	N/A	63	Mitral annular disjunction by CMR, mid-systolic click
Narayanan et al., 2016 (5)	Prospective	17	60.9 ± 16.4	29.4	54.2 ± 14.7	58.8	N/A	29	Young age, fewer comorbid conditions
Nordhues et al., 2016 (22)	Retrospective	5,669 (bi-MVP), 5,669 (single MVP)	63.5 ± 16.1	47.0	62.0 ± 7.3	46	N/A	3.7†	Bi-MVP more VT than with single-leaflet MVP
Fulton et al., 2018 (26)	Retrospective	15	48.5 ± 14.0	78.5	53 ± 8	6.6	33.3	60	Female, bi-MVP and papillary muscle fibrosis by CMR
Muthukumar et al., 2017 (25)	Retrospective	21	51.6 ± 12.3	71.0	N/A	N/A	38	47.6	Spiked systolic lateral mitral annular velocities—Pickelhaube sign
Basso et al., 2015 (6)	Retrospective	43	32	61.0	64	None	83	28	Female and papillary muscles LGE on CMR
Sriram et al., 2013 (15)	Retrospective	10 (bi-MVP)	33 ± 16	90.0	60.5 ± 3.1	50	78	100	Female, inferolateral TWI, complex ventricular ectopy, and bi-MVP
Turker et al., 2010 (23)	Retrospective	58	33.5 ± 11.2	56.0	69.7 ± 2.7	15.5	N/A	34	Moderate-severe MR
Chesler et al., 1983 (34)	Retrospective	14	27 ± 11	86.0	N/A	N/A	14‡	42.8	Endocardial friction lesions

*Median or mean ± SD. †Only ventricular tachycardia (VT) or ventricular fibrillation or SCA. ‡ST-T changes in inferior leads.

bi-MVP = bileaflet mitral valve prolapse; CMR = cardiac magnetic resonance; ECG = electrocardiogram; LVEF = left ventricular ejection fraction; MR = mitral regurgitation; MVP = mitral valve prolapse; N/A = not available; SCA = sudden cardiac arrest; TWI = T-wave inversion; VA = ventricular arrhythmia.

are multiform (pleomorphic) and occur as couplets or nonsustained ventricular tachycardia (VT) (20). The dominant PVC morphologies in MVP patients are those arising from the papillary muscle region and the outflow tract. The ectopy is presumed to be at least in part due to regional stretch, either as a consequence of direct mechanical forces or triggered activity due to damaged tissue with abnormal Ca^{2+} handling and evoked delayed afterdepolarizations (21). The presence of PVCs alone, even pleomorphic PVCs, is not enough to risk stratify a patient as it is a common finding, but it should alert the clinician to consider additional risk stratification. Perhaps a more important marker of SCD is the origin of the PVC. In a series of consecutive bileaflet MVP patients undergoing catheter ablation, a Purkinje origin PVC was identified as the ventricular fibrillation trigger in all 6 of the patients who had a prior history of cardiac arrest (7). As concluded by the authors, arrhythmic mitral valve prolapse (bileaflet) is characterized by fascicular and papillary muscle PVCs that trigger ventricular fibrillation, suggesting a central role of the Purkinje system in this condition.

ECHOCARDIOGRAPHY

Bileaflet MVP has been proposed as a high-risk feature for SCD, but there have been conflicting results regarding long-term prognosis in these patients (6,15,22). A review of 1,200 unexplained out-of-hospital cardiac arrest patients at the Mayo Clinic found a 42% prevalence of bileaflet MVP in a series of 24 young patients who survived an idiopathic out-of-hospital cardiac arrest (15). However, it should be noted that in another large retrospective series from the same institution, isolated bileaflet MVP, without additional risk factors, did not appear to significantly increase the risk of SCD or need for defibrillator implant compared with single-leaflet MVP, suggesting the importance of confirming the presence of additional risk factors (22).

Mitral regurgitation frequently develops occurs in patients with MVP and its severity appears to have a significant association with VAs in MVP, although, again, there are conflicting data (23). In 1 observational series, moderate-severe MR was an independent predictor of VAs (relative risk: 8.42); however, MVP-related SCD is also known to occur in patients with minimal-mild MR (23,24).

An easily obtainable and recently reported echocardiographic marker of arrhythmic risk involves the measurement of myocardial velocities. In patients with myxomatous bileaflet mitral valve prolapse, lateral mitral annular velocities were quantified with Doppler tissue imaging. Patients were divided into those with "Pickelhaube sign" (**Figure 1**), defined as a peak systolic lateral mitral annulus velocity of ≥16 cm/s, and those without (<16 cm/s) (25).

CENTRAL ILLUSTRATION Mitral Valve Prolapse-Related Sudden Cardiac Death: Interactions and Risk Factors

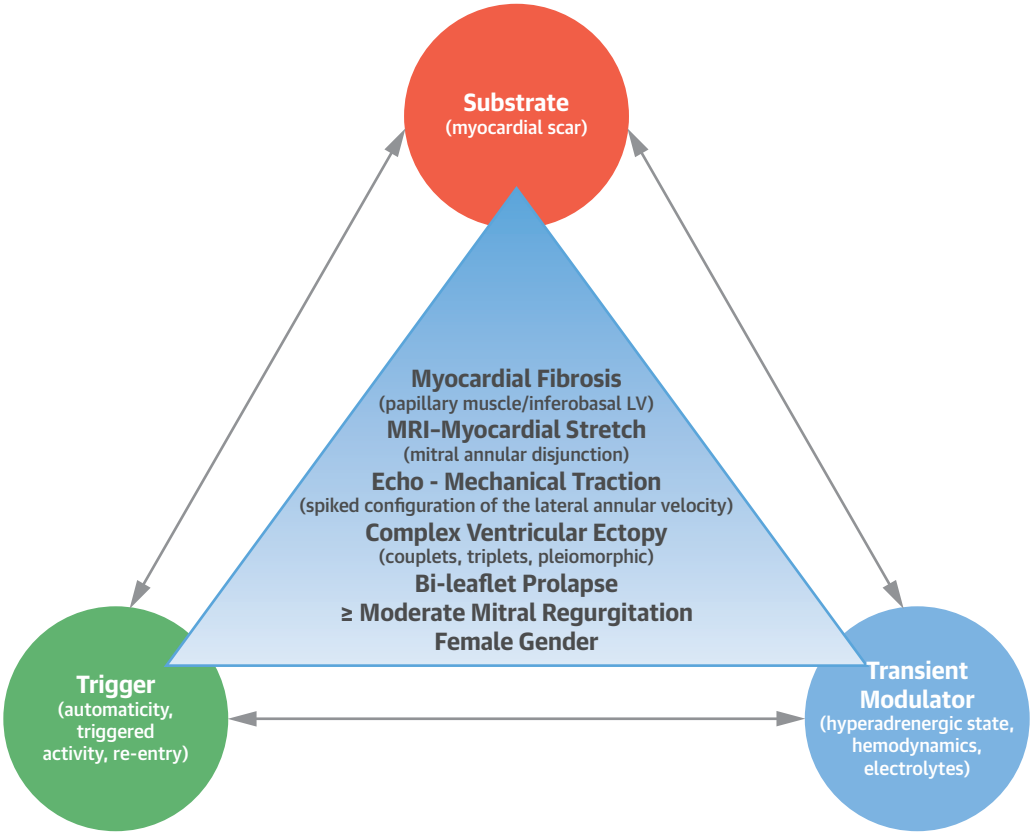

Miller, M.A. et al. J Am Coll Cardiol. 2018;72(23):2904–14.

The **inner triangle** includes clinical variables and markers that have been associated with a higher risk for developing sustained ventricular arrhythmias and sudden death in patients with mitral valve prolapse (MVP). The **outer circles** represent the interplay of factors that may contribute to sudden death in patients with MVP, including myocardial fibrosis (substrate), ventricular ectopy (trigger), and transient modulators. LV = left ventricle; MRI = magnetic resonance imaging.

The patients meeting this criterion were more likely to have had a malignant VA (67% vs. 22%; $p < 0.08$). Furthermore, delayed gadolinium enhancement (by magnetic resonance imaging [MRI]) was only present in the group with the Pickelhaube sign (33%) and not in those without it. The authors concluded that the presence of a Pickelhaube sign may be an indicator of a malignant phenotype of myxomatous bileaflet mitral valve prolapse. However, further investigation is needed to confirm their findings.

CARDIAC MRI

Cardiac MRI can help define and characterize the composition of the myocardium and identify specific arrhythmic risk factors, such as endocardial fibrosis (6,26). Basso et al. (6) examined 43 cases of SCD in young patients with MVP from the Italian cardiac pathology registry of SCD victims and performed cardiac magnetic resonance (CMR) and histopathological correlation (7). In patients with SCD and complex VAs, they found a high percentage exhibited evidence of either focal LV papillary muscle fibrosis (88%) or inferobasal fibrosis (93%) (**Figure 1**). As expected, late gadolinium enhancement (LGE) distribution on CMR correlated with histopathological fibrosis. These observations were confirmed in another independent cohort of 3,680 autopsies, of which MVP accounted for 62 (1.7%) cases (27). The authors identified LV fibrosis in 74% of cases with fibrosis involving 1 or both papillary muscles (predominantly the posteromedial papillary muscle)

JACC VOL. 72, NO. 23, 2018
DECEMBER 11, 2018:2904–14

FIGURE 1 Noninvasive Markers Associated With SCD in MVP

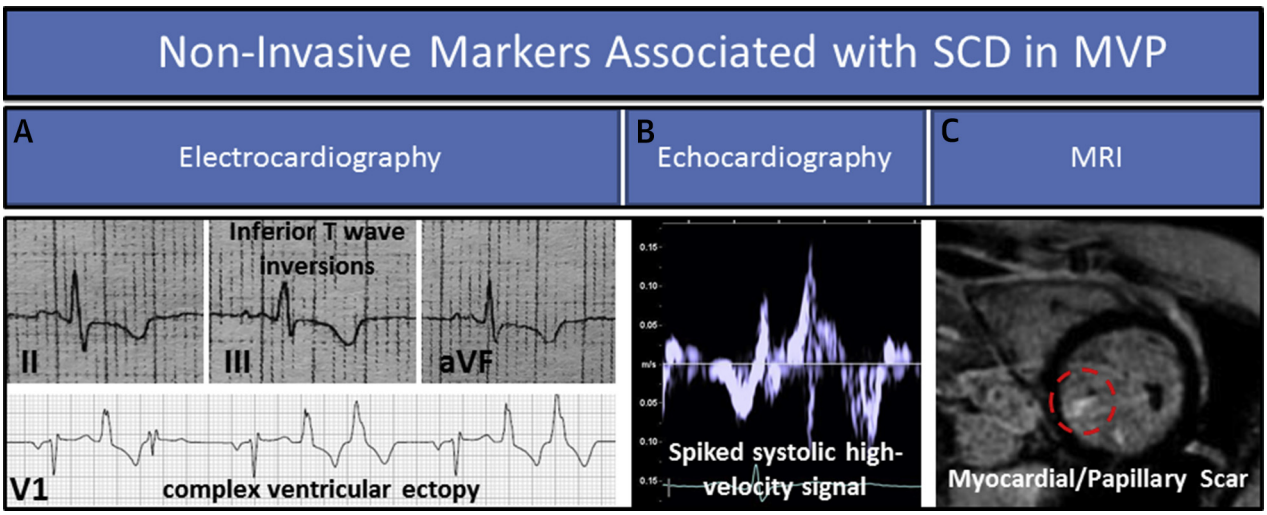

(A) Electrocardiography (inferior T-wave inversions and complex ventricular ectopy); **(B)** echocardiography (spiked systolic lateral mitral annular velocities—Pickelhaube sign); and **(C)** magnetic resonance imaging (MRI) (**red dashed circle** indicates myocardial scar in the papillary muscle). MVP = mitral valve prolapse; SCD = sudden cardiac death.

and the adjacent LV wall (predominantly the posteroinferior LV wall). The association between MVP and myocardial replacement fibrosis was recently further characterized by an elegant study of patients with primary MR due to either MVP (n = 177) or non-MVP (n = 179) etiologies. The authors demonstrated that MVP is associated with more LV fibrosis on MRI compared with non-MVP-related MR, and the fibrosis increases with MR severity, tends to occur in specific areas of the LV (suggestive of a mechanistic association), and is associated with sustained VT or ventricular fibrillation (VF). Specifically, LV fibrosis was present in 36.7% of MVP patients, compared with only 6.7% of non-MVP patients ($p < 0.001$). Furthermore, in the MVP patients, replacement fibrosis (midwall striae or patchy pattern) was most commonly found in the basal inferolateral wall (31.1%) followed by the basal inferior wall (10.7%). During follow-up, arrhythmic events (defined as SCD, or spontaneous or induced sustained VT) occurred in 4.5% (n = 8) of the MVP patients. The highest arrhythmic event rate was seen in MVP patients with replacement fibrosis (7.7%), followed by MVP patients without replacement fibrosis (2.7%) and non-MVP patients (0.6%; $p < 0.01$) (28).

The presence of diffuse subclinical interstitial fibrosis by CMR in patients with MVP with MR was also reported by Bui et al. (29). They showed that the presence of diffuse nonfocal subclinical ventricular fibrosis was associated with complex VAs. The authors suggested that subclinical diffuse fibrosis maybe a precursor of focal fibrosis in MVP or a separate disease entity involving up-regulation of fibrotic markers could be a marker for early identification of patients at risk of SCD.

Recently, mitral annulus disjunction (MAD) was reported to be a constant component of arrhythmic MVP with LV fibrosis (30). MAD is detachment of the roots of the annulus from the ventricular myocardium (i.e., ventriculoannular detachment), which is localized to the base of the posterior leaflet (31). In a study including 36 patients with MVP, MAD was significantly longer (4.8 mm) in those with LGE on MRI, compared with those who did not have LGE on MRI (1.8 mm; $p < 0.001$). However, the study did not provide a specific threshold limit (distance) of MAD that was associated with an increased risk of VAs; therefore, these findings require further validation in independent cohorts. **Figure 2** is an example of a patient who first presented with SCD due to ventricular fibrillation and MAD (12.7 mm) by MRI. It should also be noted that transthoracic echocardiography has been used to assess MAD in patients with myxomatous mitral valve disease, and the severity of MAD is associated with VA burden. For example, a disjunction length of >8.5 mm correctly identified 67% of the patients who exhibited nonsustained VT on Holter monitoring (32).

FIGURE 2 Arrhythmic Mitral Valve Prolapse Diagnosed After Out-of-Hospital Cardiac Arrest

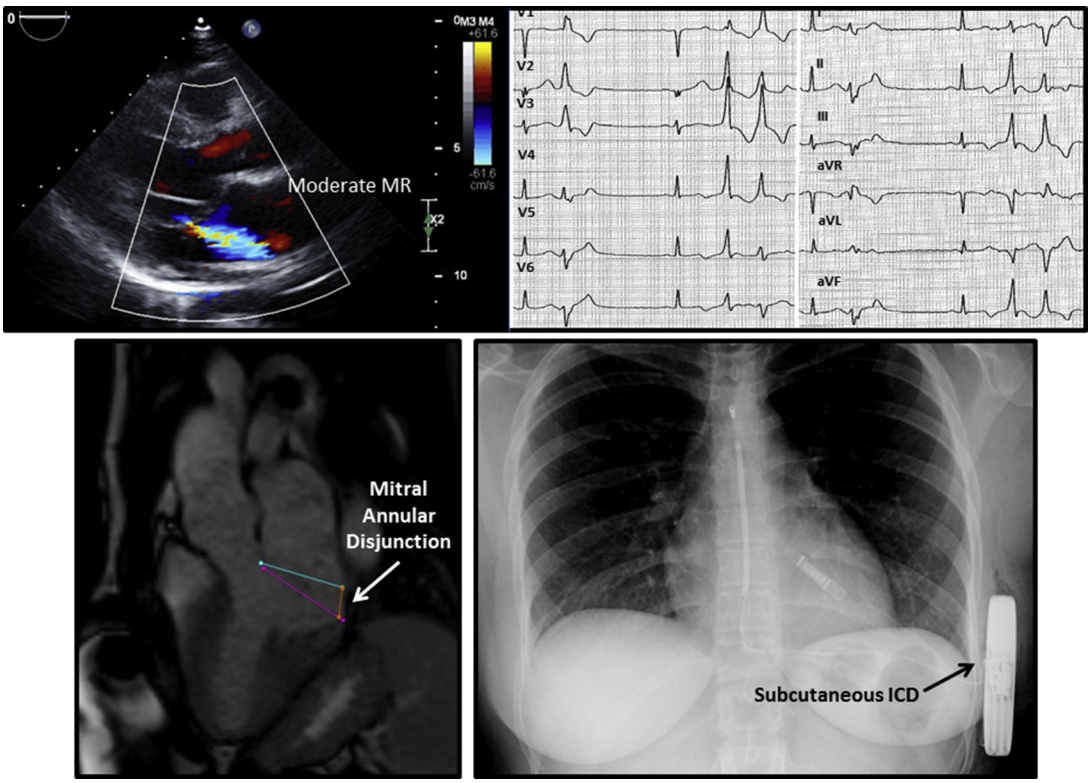

Example of patient whose first presentation of mitral valve prolapse was due to witnessed out-of-hospital cardiac arrest (ventricular fibrillation). Echocardiogram with posterior leaflet prolapse and moderate mitral regurgitation **(top left)**, electrocardiogram with complex ventricular ectopy **(top right)**, cardiac magnetic resonance image (3 chamber, long axis) of prominent mitral annular disjunction (12.7 mm) **(bottom left)**, and chest x-ray following implantation of a secondary prevention subcutaneous implantable cardioverter-defibrillator (ICD) **(bottom right)**. MR = mitral regurgitation.

PROPOSED MECHANISM OF VAs: SUBSTRATE, TRIGGER, AND TRANSIENT MODULATOR

Two common findings in patients with MVP-related SCD are: 1) LV myocardial fibrosis (substrate); and 2) complex ventricular ectopy (trigger). Perhaps a consequence of mechanical traction exerted by the prolapsing leaflet, the fibrosis is most often localized to the inferolateral base of the left ventricle or the papillary muscles, which are most susceptible to the mechanical stretch forces exerted by the billowing leaflets (14). With continued mechanical traction by the prolapsing leaflet, myocardial hypertrophy, and a replacement fibrosis can occur in those structures that support the mitral apparatus—the basal and mid-inferolateral ventricle and the papillary muscles (33). Additionally, it has been postulated that friction between the chordae and the LV endocardium can result in "friction lesions," characterized by the development of endocardial fibrosis between the papillary muscle and the annulus (34). The mechanically induced LV fibrosis likely acts as the substrate, which increases the vulnerability by either triggered activity or re-entry of these patients to both the development and maintenance of sustained ventricular tachyarrhythmia (35). **Figure 3** is an example of a middle-aged man who was being routinely followed for asymptomatic MVP but experienced a witnessed out-of-hospital cardiac arrest (VF); he was subsequently found to have delayed enhancement in the posterobasal LV.

PREMATURE VENTRICULAR CONTRACTIONS. As noted previously, a majority of patients with MVP who experienced SCD have a history of complex PVCs (**Figure 1**). Acute myocardial stretch can cause shortening of the action potential duration, a decrease in resting diastolic potential, and the development of

JACC VOL. 72, NO. 23, 2018
DECEMBER 11, 2018:2904–14

FIGURE 3 Cardiac Arrest in a Patient With Asymptomatic MVP With Moderate Mitral Regurgitation

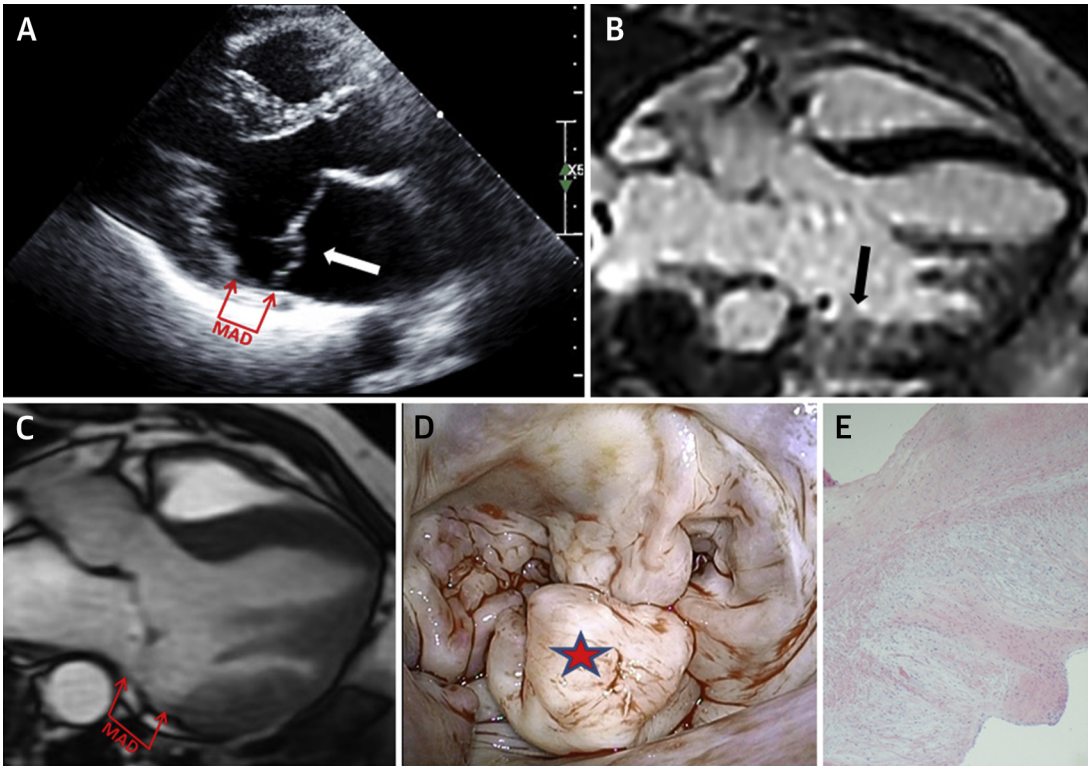

A middle-aged man who was known to have mitral valve prolapse (MVP) (posterior leaflet) with mild-moderate mitral regurgitation. He remained asymptomatic and was recommended routine follow-up. He presented to our institution after a witnessed out-of-hospital cardiac arrest (ventricular fibrillation). **(A)** Echocardiogram demonstrating classic prolapse of the posterior leaflet **(open arrow)** and mitral annular disjunction (MAD) **(red arrows)**. **(B)** Cardiac magnetic resonance imaging with delayed enhancement demonstrating predominantly subendocardial scar in the mid-inferior and mid-inferolateral segments **(solid arrow)**. **(C)** Cardiac magnetic resonance imaging (3-chamber view) demonstrating MAD of 13 mm **(red arrows)**. **(D)** Intraoperative image of his mitral valve repair surgery, demonstrating severe myxomatous degeneration of the posterior leaflet (P1-P2) **(star)**. **(E)** Histopathology (hematoxylin and eosin stain) demonstrating myxomatous degeneration of the posterior leaflet tissue.

stretch-activated early afterdepolarizations (36,37). The papillary muscles are exposed to these acute stretch forces by the prolapsing leaflet, and the papillary muscles distal Purkinje fibers which are prone to afterdepolarization and abnormal automaticity. In fact, in patients with bileaflet prolapse and prior cardiac arrest undergoing catheter ablation, Purkinje signals commonly precede the VF, triggering PVCs (15).

TRANSIENT MODULATOR: AUTONOMIC NERVOUS SYSTEM AND CATECHOLAMINES. Autonomic dysfunction, including elevated sympathetic and diminished vagal tone, are known to occur in patients with MVP (38). This hyperadrenergic state can increase the frequency of ventricular ectopy, as well as the predisposition of the ventricular myocardium to that ectopic activity (23,38). The prolapsing mitral valve delivers traction on the papillary muscles, activating the local stretch receptors and causing membrane depolarization of the nerve endings with abnormal mechanoelectrical feedback to the central nervous system causing VT or VF (39,40). In addition, the enhanced catecholamine levels can cause downstream ion-channel modulation and Ca^{+2} loading in the sarcoplasmic reticulum, resulting in delayed afterdepolarization and subsequently contributing to VAs (41,42). Ultimately, it is the combination of circumstances, such as short-coupled mechanically triggered PVCs from a structural or fibrotic abnormality from the mitral valve apparatus combined with heightened autonomic tone, that sets the stage for the development of SCD in the vulnerable patient. The **Central Illustration** depicts the interaction among the substrate (scar), trigger (PVCs), and a transient event

(e.g., heightened autonomic tone) that can precipitate a sustained VA.

RISK STRATIFICATION

Although there are several risk factors that predict SCD in MVP, there is no single risk factor that has proved to be a consistent predictor of malignant VAs and SCD. Furthermore, it is not yet known which combination of risk factors predisposes patients to higher risk. The challenge of risk stratification in MVP is identifying the high-risk patient concealed within a large population of low-risk patients. Nevertheless, we believe that a focused work-up can be performed to stratify the patient into a low-risk or high-risk category (**Central Illustration**). As previously mentioned, most patients with MVP-related SCD have complex ventricular ectopy (trigger) and myocardial scar (substrate), and therefore a work-up should include an assessment of these factors. The available literature suggests that female sex, bileaflet MVP, history of complex ventricular ectopy, and LGE on CMR are readily identifiable features that can be used to categorize patients as higher or lower risk (6,15,26). With regard to detecting nonsustained VT, in a patient population of MVP patients without arrhythmic symptoms, the estimated sensitivity of the 12-lead ECG, treadmill ECG, and 24-h ambulatory Holter monitor was 17%, 50%, and 83%, respectively (43). In our own practice, we recommend extended rhythm monitoring (either 24-h Holter or 7-day external event recorder) to assess the burden of VAs, even in asymptomatic patients. In patients with MVP and unexplained syncope, we would recommend a thorough diagnostic evaluation to determine if the patient has true arrhythmic syncope. Clinical features suggestive of arrhythmic syncope include syncope during strenuous exercise, while sitting or in the supine position, sudden-onset palpitations before the syncopal event, and absence of any warning symptoms immediately prior. For patients with MVP, suspected arrhythmic syncope, and evidence of myocardial scar, it would be appropriate to consider either an electrophysiology study. If the electrophysiology study is negative or not performed, a loop recorder implant for long-term rhythm monitoring should be strongly considered in any patient, especially if other high-risk features are present (e.g., bileaflet prolapse, complex ventricular ectopy) (44).

For patients who have evidence of complex VAs or echocardiographic evidence of mechanical traction of the papillary muscles or ventricular myocardium (e.g., Pickelhaube sign), we recommend CMR to assess for myocardial scar. In our own practice, we consider performing an electrophysiology study for risk stratification for patients with multiple risk factors, such as those with evidence of a trigger (pleomorphic PVCs) and substrate (myocardial scar). It should be acknowledged that programmed electrical ventricular stimulation to risk stratify MVP patients is not well established, as it is with other substrates that predispose to SCD (45). The induction of polymorphic VT and VF with aggressive stimulation protocols in patients with a history of complex VAs is a nonspecific finding and does not necessarily predict future risk of SCD. However, the few studies assessing the role of programmed ventricular stimulation in an MVP patient population did not include more conventional risk factors, such as presence of myocardial scar. We define a positive electrophysiology study as sustained monomorphic VT, which is induced with up to 3 ventricular extrastimuli or polymorphic VT or VF induced with up to 2 ventricular extrastimuli. In those patients with a "positive" electrophysiology study, we recommend implantation of an implantable cardioverter-defibrillator. However, it is important to recognize that additional studies are needed to understand the prognostic ability of programmed electrical ventricular stimulation in this heterogenous patient population.

RECOMMENDATIONS

The American Heart Association/European Society of Cardiology guidelines for VAs and SCD have no specific recommendations for the risk stratification of SCD in MVP (46). The management of low-risk MVP patients with pleomorphic VAs needs to be conservative, with surveillance cardiac monitoring with or without medications. Beta-blockers are the preferred first-line agents for the management of symptomatic or asymptomatic nonsustained or sustained VAs (46). It is recommended that patients avoid stimulants such as caffeine, alcohol, tobacco, and other illicit drugs that can increase catecholamine levels (47). Recommendations for exercise are included in the Online Appendix. Online Figure 1 is an example of exercise-induced ventricular tachycardia.

CATHETER ABLATION

Due to the diverse conditions that are involved in initiating malignant VAs in MVP, it can be appreciated that catheter ablation is reserved for cases where electrical triggers of VT or VF can be mapped and identified or for scar-related re-entrant VT (7,48). As for the former, the procedure involves mapping of

FIGURE 4 Monomorphic Ventricular Tachycardia Following Mitral Valve Repair for Mitral Valve Prolapse

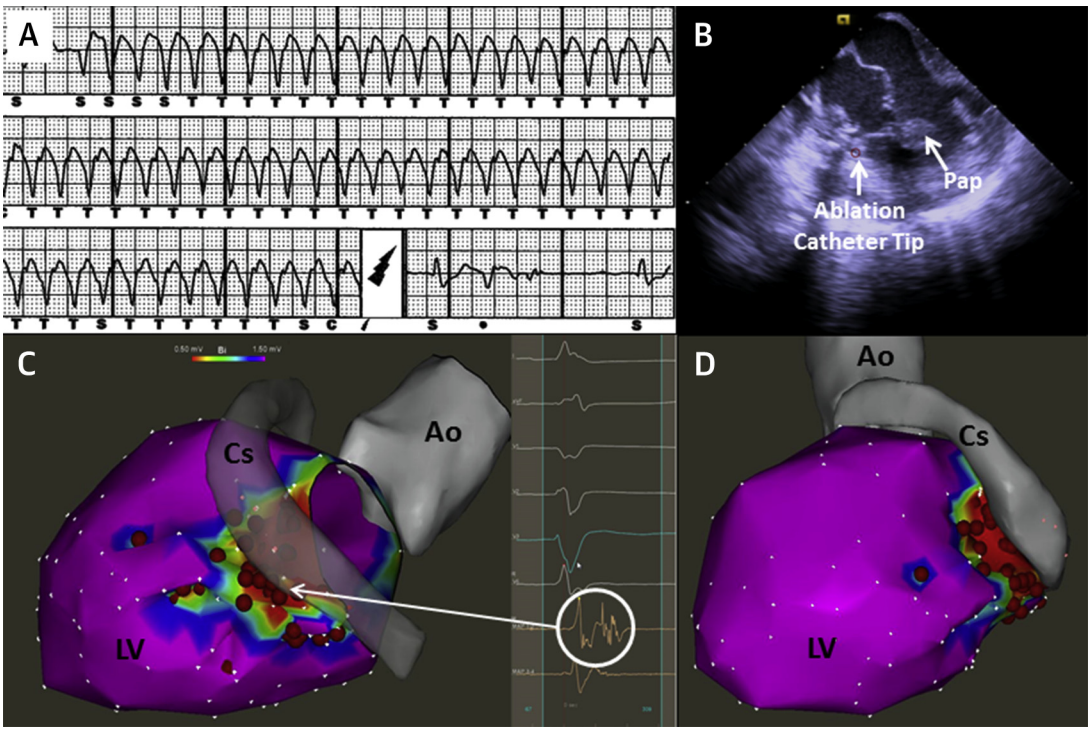

Example of a patient who underwent implantation of a secondary prevention subcutaneous implantable cardioverter-defibrillator (ICD) implant approximately 1 year after mitral valve repair for mitral valve prolapse with severe mitral regurgitation. **(A)** He subsequently represented following an appropriate ICD shock for sustained monomorphic ventricular tachycardia. Also shown is the location of the tip of the ablation catheter on intracardiac ultrasound, **(B)** at the basal lateral aspect of the left ventricle (LV), as well as **(C, D)** bipolar voltage maps of the LV endocardium, with the scar localized to the basal lateral LV. Voltages were color-coded according to the corresponding **color bar**. Scar tissue **(red)**, border zone, and normal myocardium **(purple)** were defined as bipolar cutoff values of ≤0.5 mV, 0.5 to 1.5 mV, and >1.5 mV, respectively. Programmed stimulation from the right ventricle induced 4 hemodynamically unstable ventricular tachycardias, which were either pace-terminated or cardioverted. Endocardial substrate-based ablation, targeting late potentials and fractionated electrograms, was performed. At the end of the procedure, the patient was noninducible for any sustained ventricular arrhythmias. **Red tags** denote ablation lesions. **(C)** The **white circle with arrow** is an example of a late-potential and its corresponding location on the map. Ao = aorta; Cs = coronary sinus; Pap = papillary muscle.

PVC triggers, which are often preceded by Purkinje potentials, and often located on the papillary muscles or within the fascicular conduction system (49). A small case series including 14 patients with bileaflet MVP with and without VF arrest who underwent catheter ablation reported a high rate of acute procedural success (89%) and a substantial reduction in implantable cardioverter-defibrillator therapies (7). As mentioned, there is a subset of patients who can develop scar-related re-entrant VT. The scar is often located at the inferobasal or inferolateral LV, the typical locations identified in imaging studies of MVP patients. **Figure 4** is an example of a patient with prior MV repair who developed sustained monomorphic VT.

MITRAL VALVE SURGERY

Mitral valve repair should theoretically relieve stretch on the papillary muscles and facilitate ventricular remodeling, leading to a reduction in VAs. The current literature regarding the role of mitral valve repair or replacement in reducing VAs is mixed and comes from isolated case reports or single-center experiences with small sample sizes (50). Mitral valve surgery was found to be beneficial in reducing VAs in a few studies including younger patients (~42 years of age) but not in older patients (~62 years of age) (50–52). The progressive nature of the arrhythmic substrate and extent of fibrosis in the papillary muscles, chordae tendinae, and mitral annulus with age

and associated comorbid conditions are probably the reason for this observation. Furthermore, older patients can have diffuse fibrosis (rather than focal) and additional myocardial substrate such as presence of idiopathic outflow tract ectopy, which cannot be treated with surgery of the mitral apparatus alone. The role of surgical cryoablation during mitral valve surgery in patients with history of VAs has been reported with no long-term data on clinical outcomes, but it can be considered in select patients (53). A collective input from a heart team consisting of cardiac surgeons, electrophysiologists, and imaging specialists is needed for optimal decision-making.

DEFIBRILLATOR IMPLANT

Currently, there are insufficient data supporting the role of prophylactic implantable cardioverter-defibrillator implantation in patients with MVP and high-risk features. As previously mentioned, in our institution, we consider an electrophysiology study for risk stratification in patients with MVP who have evidence of a trigger (pleiomorphic PVCs) and substrate (myocardial scar in typical locations). We consider implantation of a primary prevention implantable cardioverter-defibrillator if sustained monomorphic VT was induced with up to 3 ventricular extrastimuli or sustained polymorphic VT was induced with either 1 or 2 ventricular extrastimuli (54). However, we acknowledge that there is no randomized evidence to support the use of programmed stimulation to risk-stratify patients with MVP, and this approach is based on personal practice. The positive and negative predictive values of programmed ventricular stimulation remain unknown, and both the results of stimulation could be influenced by the site of stimulation (e.g., right ventricular apex vs. closer to the LV substrate), as well as the number and coupling intervals of the extrastimuli. Therefore, although programmed stimulation could overestimate the risk of sudden death in cases where the test was "positive" or provide false reassurance if the test was "negative," it may be considered in patients with the aforementioned risk profile (trigger and substrate).

CONCLUSIONS

There is an association between MVP and SCD. It would be prudent to identify and stratify at-risk patients. A majority of patients who experienced MVP-related sudden death had evidence of a trigger (PVCs) and the substrate (myocardial strain or fibrosis) necessary to initiate and perpetuate malignant VAs. Future longitudinal studies are needed to advance our understanding of the mechanisms of MVP-related SCD, validate existing risk factors, and identify the highest-risk patients who could potentially benefit from a primary prevention intervention.

ADDRESS FOR CORRESPONDENCE: Dr. Marc A. Miller, Helmsley Electrophysiology Center, Icahn School of Medicine at Mount Sinai, One Gustave Levy Place, New York, New York 10029. E-mail: marc.miller@mssm.edu. Twitter: @IcahnMountSinai, @SriniDukkipati.

REFERENCES

1. Delling FN, Rong J, Larson MG, et al. Evolution of mitral valve prolapse: insights from the Framingham Heart Study. Circulation 2016;133:1688–95.

2. Avierinos JF, Gersh BJ, Melton LJ 3rd, et al. Natural history of asymptomatic mitral valve prolapse in the community. Circulation 2002;106:1355–61.

3. Nishimura RA, McGoon MD, Shub C, Miller FA Jr., Ilstrup DM, Tajik AJ. Echocardiographically documented mitral-valve prolapse. Long-term follow-up of 237 patients. N Engl J Med 1985;313:1305–9.

4. Anders S, Said S, Schulz F, Puschel K. Mitral valve prolapse syndrome as cause of sudden death in young adults. Forensic Sci Int 2007;171:127–30.

5. Narayanan K, Uy-Evanado A, Teodorescu C, et al. Mitral valve prolapse and sudden cardiac arrest in the community. Heart Rhythm 2016;13:498–503.

6. Basso C, Perazzolo Marra M, Rizzo S, et al. Arrhythmic mitral valve prolapse and sudden cardiac death. Circulation 2015;132:556–66.

7. Syed FF, Ackerman MJ, McLeod CJ, et al. Sites of successful ventricular fibrillation ablation in bileaflet mitral valve prolapse syndrome. Circ Arrhythm Electrophysiol 2016;9:e004005.

8. Kuriachan VP, Sumner GL, Mitchell LB. Sudden cardiac death. Curr Probl Cardiol 2015;40:133–200.

9. Campuzano O, Sanchez-Molero O, Fernandez A, et al. Sudden arrhythmic death during exercise: a post-mortem genetic analysis. Sports Med 2017;47:2101–15.

10. Oliva A, Brugada R, D'Aloja E, et al. State of the art in forensic investigation of sudden cardiac death. Am J Forensic Med Pathol 2011;32:1–16.

11. Chugh SS, Chung K, Zheng ZJ, John B, Titus JL. Cardiac pathologic findings reveal a high rate of sudden cardiac death of undetermined etiology in younger women. Am Heart J 2003;146:635–9.

12. Maron BJ, Haas TS, Ahluwalia A, Murphy CJ, Garberich RF. Demographics and epidemiology of sudden deaths in young competitive athletes: from the United States National Registry. Am J Med 2016;129:1170–7.

13. Finocchiaro G, Papadakis M, Robertus JL, et al. Etiology of sudden death in sports: insights from a United Kingdom regional registry. J Am Coll Cardiol 2016;67:2108–15.

14. Basso C, Calabrese F, Corrado D, Thiene G. Postmortem diagnosis in sudden cardiac death victims: macroscopic, microscopic and molecular findings. Cardiovasc Res 2001;50:290–300.

15. Sriram CS, Syed FF, Ferguson ME, et al. Malignant bileaflet mitral valve prolapse syndrome in patients with otherwise idiopathic out-of-hospital cardiac arrest. J Am Coll Cardiol 2013;62:222–30.

16. Zuppiroli A, Mori F, Favilli S, et al. Arrhythmias in mitral valve prolapse: relation to anterior mitral leaflet thickening, clinical variables, and color

Doppler echocardiographic parameters. Am Heart J 1994;128:919–27.

17. Avierinos JF, Inamo J, Grigioni F, Gersh B, Shub C, Enriquez-Sarano M. Sex differences in morphology and outcomes of mitral valve prolapse. Ann Intern Med 2008;149:787–95.

18. Bhutto ZR, Barron JT, Liebson PR, Uretz EF, Parrillo JE. Electrocardiographic abnormalities in mitral valve prolapse. Am J Cardiol 1992;70:265–6.

19. Kligfield P, Hochreiter C, Kramer H, et al. Complex arrhythmias in mitral regurgitation with and without mitral valve prolapse: contrast to arrhythmias in mitral valve prolapse without mitral regurgitation. Am J Cardiol 1985;55:1545–9.

20. Lown B, Wolf M. Approaches to sudden death from coronary heart disease. Circulation 1971;44:130–42.

21. Maruyama T, Fukata M. Increased coupling interval variability—mechanistic, diagnostic and prognostic implication of premature ventricular contractions and underlying heart diseases. Circ J 2015;79:2317–9.

22. Nordhues BD, Siontis KC, Scott CG, et al. Bileaflet mitral valve prolapse and risk of ventricular dysrhythmias and death. J Cardiovasc Electrophysiol 2016;27:463–8.

23. Turker Y, Ozaydin M, Acar G, et al. Predictors of ventricular arrhythmias in patients with mitral valve prolapse. Int J Cardiovasc Imaging 2010;26:139–45.

24. Dollar AL, Roberts WC. Morphologic comparison of patients with mitral valve prolapse who died suddenly with patients who died from severe valvular dysfunction or other conditions. J Am Coll Cardiol 1991;17:921–31.

25. Muthukumar L, Rahman F, Jan MF, et al. The Pickelhaube sign: novel echocardiographic risk marker for malignant mitral valve prolapse syndrome. J Am Coll Cardiol Img 2017;10:1078–80.

26. Fulton BL, Liang JJ, Enriquez A, et al. Imaging characteristics of papillary muscle site of origin of ventricular arrhythmias in patients with mitral valve prolapse. J Cardiovasc Electrophysiol 2018;29:146–53.

27. Sheppard MN, Steriotis AK, Sharma S. Letter by Sheppard et al regarding article, "arrhythmic mitral valve prolapse and sudden cardiac death." Circulation 2016;133:e458.

28. Kitkungvan D, Nabi F, Kim RJ, et al. Myocardial fibrosis in patients with primary mitral regurgitation with and without prolapse. J Am Coll Cardiol 2018;72:823–34.

29. Bui AH, Roujol S, Foppa M, et al. Diffuse myocardial fibrosis in patients with mitral valve prolapse and ventricular arrhythmia. Heart 2017;103:204–9.

30. Perazzolo Marra M, Basso C, De Lazzari M, et al. Morphofunctional abnormalities of mitral annulus and arrhythmic mitral valve prolapse. Circ Cardiovasc Imaging 2016;9:e005030.

31. Enriquez-Sarano M. Mitral annular disjunction: the forgotten component of myxomatous mitral valve disease. J Am Coll Cardiol Img 2017;10:1434–6.

32. Carmo P, Andrade MJ, Aguiar C, Rodrigues R, Gouveia R, Silva JA. Mitral annular disjunction in myxomatous mitral valve disease: a relevant abnormality recognizable by transthoracic echocardiography. Cardiovasc Ultrasound 2010;8:53.

33. Huttin O, Pierre S, Venner C, et al. Interactions between mitral valve and left ventricle analysed by 2D speckle tracking in patients with mitral valve prolapse: one more piece to the puzzle. Eur Heart J Cardiovasc Imaging 2017;18:323–31.

34. Chesler E, King RA, Edwards JE. The myxomatous mitral valve and sudden death. Circulation 1983;67:632–9.

35. Disertori M, Rigoni M, Pace N, et al. Myocardial fibrosis assessment by LGE is a powerful predictor of ventricular tachyarrhythmias in ischemic and nonischemic LV dysfunction: a meta-analysis. J Am Coll Cardiol Img 2016;9:1046–55.

36. Franz MR. Mechano-electrical feedback. Cardiovasc Res 2000;45:263–6.

37. Lab MJ. Mechanoelectric feedback (transduction) in heart: concepts and implications. Cardiovasc Res 1996;32:3–14.

38. Sniezek-Maciejewska M, Dubiel JP, Piwowarska W, et al. Ventricular arrhythmias and the autonomic tone in patients with mitral valve prolapse. Clin Cardiol 1992;15:720–4.

39. Tavi P, Han C, Weckstrom M. Mechanisms of stretch-induced changes in [Ca2+]i in rat atrial myocytes: role of increased troponin C affinity and stretch-activated ion channels. Circ Res 1998;83:1165–77.

40. Franz MR, Cima R, Wang D, Profitt D, Kurz R. Electrophysiological effects of myocardial stretch and mechanical determinants of stretch-activated arrhythmias. Circulation 1992;86:968–78.

41. Myles RC, Wang L, Kang C, Bers DM, Ripplinger CM. Local β-adrenergic stimulation overcomes source-sink mismatch to generate focal arrhythmia. Circ Res 2012;110:1454–64.

42. Theofilogiannakos EK, Boudoulas KD, Gawronski BE, et al. Floppy mitral valve/mitral valve prolapse syndrome: Beta-adrenergic receptor polymorphism may contribute to the pathogenesis of symptoms. J Cardiol 2015;65:434–8.

43. Winkle RA, Lopes MG, Fitzgerald JW, Goodman DJ, Schroeder JS, Harrison DC. Arrhythmias in patients with mitral valve prolapse. Circulation 1975;52:73–81.

44. Brignole M, Moya A, de Lange FJ, et al. 2018 ESC Guidelines for the diagnosis and management of syncope. Eur Heart J 2018;39:1883–948.

45. Morady F, Shen E, Bhandari A, Schwartz A, Scheinman MM. Programmed ventricular stimulation in mitral valve prolapse: analysis of 36 patients. Am J Cardiol 1984;53:135–8.

46. Al-Khatib SM, Stevenson WG, Ackerman MJ, et al. 2017 AHA/ACC/HRS guideline for management of patients with ventricular arrhythmias and the prevention of sudden cardiac death. J Am Coll Cardiol 2018;72:e91–220. Erratum in: J Am Coll Cardiol 2018;72:1760.

47. Solomon RJ. Ventricular arrhythmias in patients with myocardial infarction and ischaemia. Relationship to serum potassium and magnesium. Drugs 1984;28 Suppl 1:66–76.

48. Hong T, Yang M, Zhong L, et al. Ventricular premature contraction associated with mitral valve prolapse. Int J Cardiol 2016;221:1144–9.

49. Sinha AM, Schmidt M, Marschang H, et al. Role of left ventricular scar and Purkinje-like potentials during mapping and ablation of ventricular fibrillation in dilated cardiomyopathy. Pacing Clin Electrophysiol 2009;32:286–90.

50. Naksuk N, Syed FF, Krittanawong C, et al. The effect of mitral valve surgery on ventricular arrhythmia in patients with bileaflet mitral valve prolapse. Indian Pacing and Electrophysiol J 2016;16:187–91.

51. Pocock WA, Barlow JB, Marcus RH, Barlow CW. Mitral valvuloplasty for life-threatening ventricular arrhythmias in mitral valve prolapse. Am Heart J 1991;121:199–202.

52. Vaidya VR, DeSimone CV, Damle N, et al. Reduction in malignant ventricular arrhythmia and appropriate shocks following surgical correction of bileaflet mitral valve prolapse. J Interv Card Electrophysiol 2016;46:137–43.

53. Van Dessel PF, Van Hemel NM, Van Swieten HA, De Bakker JM, Jessurun ER. Successful surgical ablation of sustained ventricular tachycardia associated with mitral valve prolapse guided by a multielectrode basket catheter. Pacing Clin Electrophysiol 2001;24:1029–31.

54. Thomas KE, Josephson ME. The role of electrophysiology study in risk stratification of sudden cardiac death. Prog Cardiovasc Dis 2008;51:97–105.

KEY WORDS mitral valve prolapse, premature ventricular contractions, sudden cardiac death

APPENDIX For expanded future areas of research and references sections, please see the online version of this paper.